

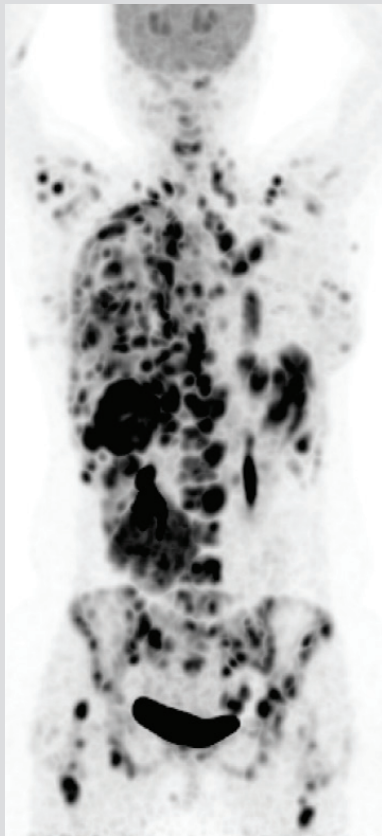
## Case Study – II

### Stage IV Invasive Ductal Carcinoma of Breast (TNBC\*) 22 year old female patient

Clinical History	
Aug '16	<b>Diagnosis: IDC Left Breast</b>
Aug – Jan '16	Cyclophosphamide + Doxorubicin + Docetaxel
Nov '16	Left Mastectomy
Feb – Mar '17	Radiotherapy
May – Jun '17	Methotrexate + Cyclophosphamide
Jun – Jul '17	Everolimus
Jul '17	<b>PET-CT: Progression</b>

exacta® rationale for therapy selection		
Gene / Pathway / Analysis	Feature	Therapeutic Implication
PDGFRA, KIT, KDR	Gain of Copy	Axitinib
Chemosensitivity	Cytotoxicity	Carboplatin Gemcitabine

### Benefit from exacta® – recommended therapy

<p><b>before</b></p> <p>Cancer had progressed following 5 lines of therapy.</p>		<p><b>after</b></p> <p>Administration of exacta®: recommended therapy led to regression of cancer.</p>
<b>day 0</b>		<b>day 34</b>

\*TNBC: Triple negative breast cancer